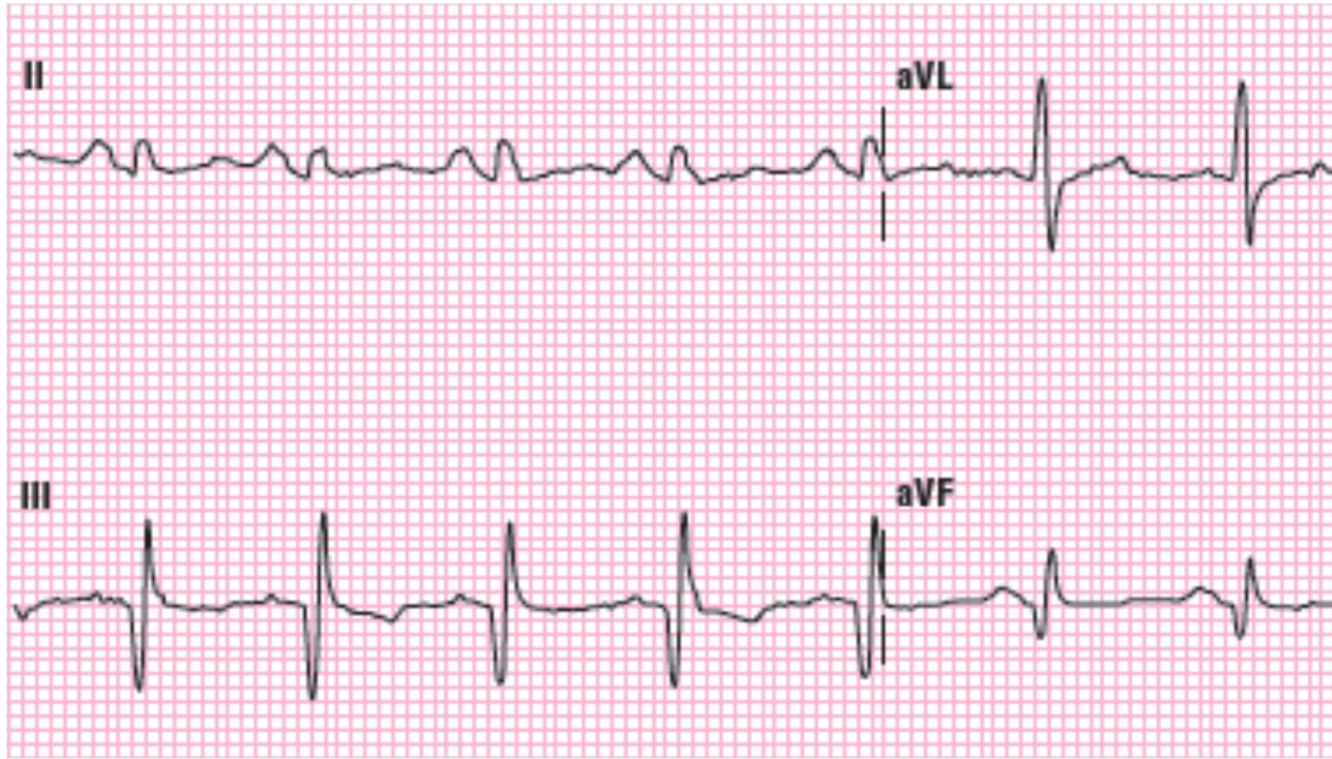


- Inferior (age indeterminate or old)



- Abnormal Q waves ( $\geq 30$  msec long, and  $\geq 1$  mm deep) *without* significant ST elevation in at least two contiguous leads II, III, aVF
- An isolated Q wave in lead III is within normal limits