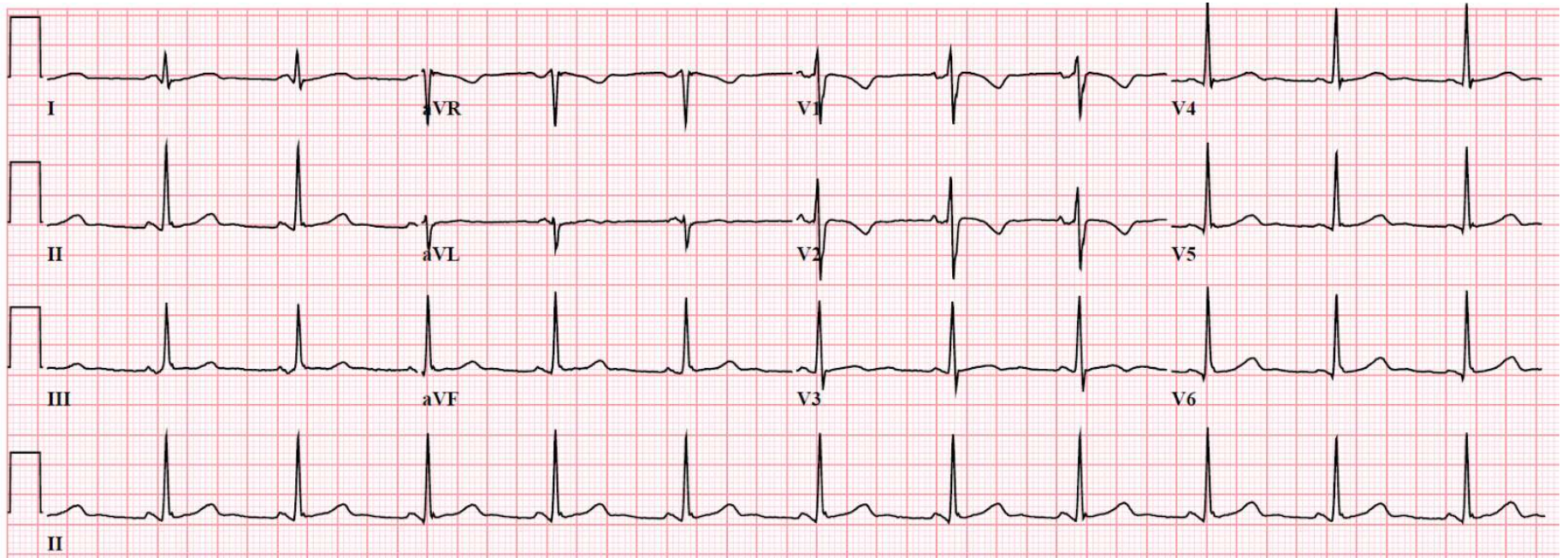


- Juvenile T waves, normal variant



- Persistently negative T waves (usually not symmetrical or deep) in leads V1–V3 in normal adults
- T waves still upright in leads I, II, V5, V6

Juvenile T waves is a normal variant ECG finding commonly seen in children and adolescents, occasionally seen as a normal variant in adult women, but only rarely seen in adult men.