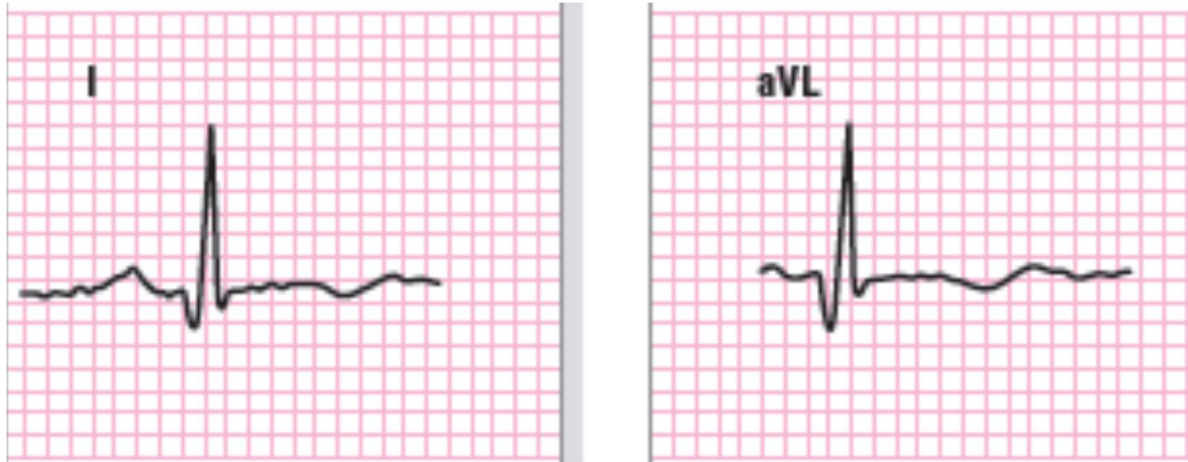


- Lateral MI (age indeterminate or old)



- Abnormal Q waves *without* significant ST segment elevation in leads I and aVL

An isolated Q wave in aVL does not qualify as a lateral MI.

- Any Q wave ≥ 30 msec (\geq three-quarters of one small box on the ECG grid) in leads I, aVL. Pathologic Q waves must be present in both leads and must be ≥ 1 mm in depth.