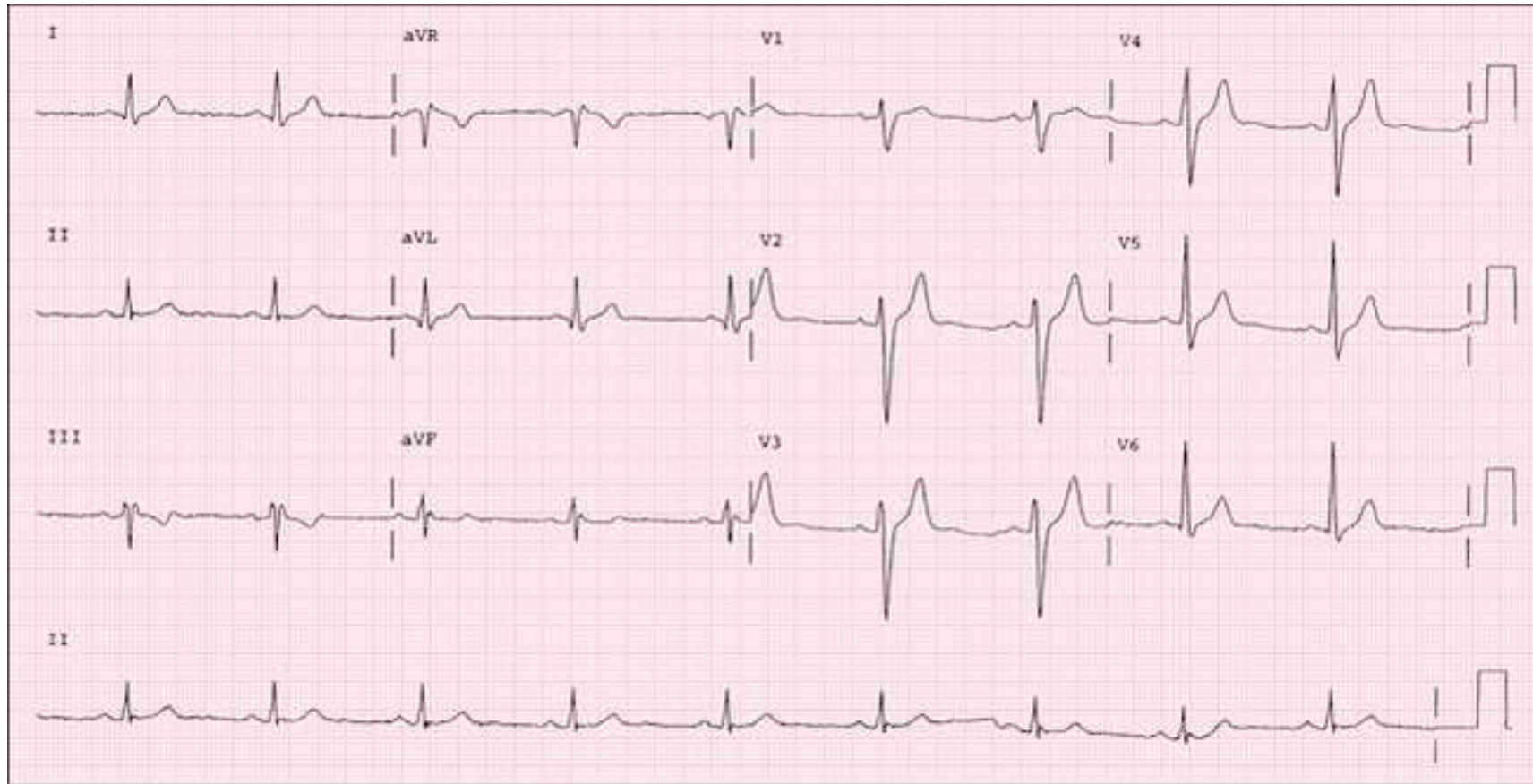


- Nonspecific intraventricular conduction disturbance (IVCD)



- QRS duration ≥ 110 msec, but morphology does not meet criteria for LBBB, RBBB, or
- Abnormal notching of the QRS complex without prolongation

Nonspecific IVCD may be seen with:

- Antiarrhythmic drug toxicity (especially Type IA and IC agents)
- Hyperkalemia
- LVH
- WPW
- Hypothermia
- Severe metabolic disturbances
- Cardiomyopathy
- Prior MI (peri-infarctional conduction defect, manifest as abnormal notching of the QRS in leads where infarct occurred)