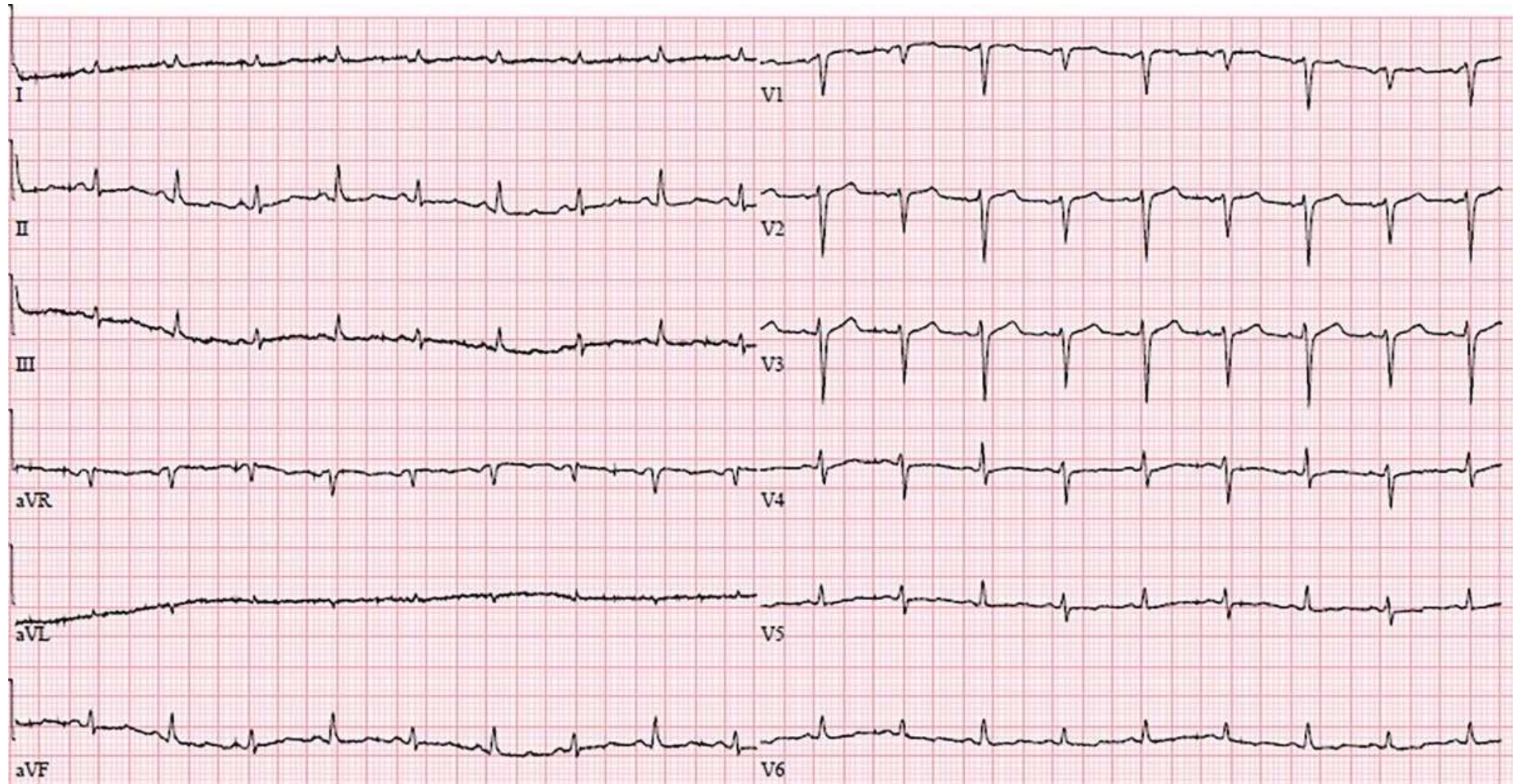


- Pericardial effusion



- Low-voltage QRSs, sinus tachycardia and electrical alternans are the 3 cardinal ECG features of pericardial tamponade
- Other features of acute pericarditis may or may not be present