• Posterior MI (age recent or acute)

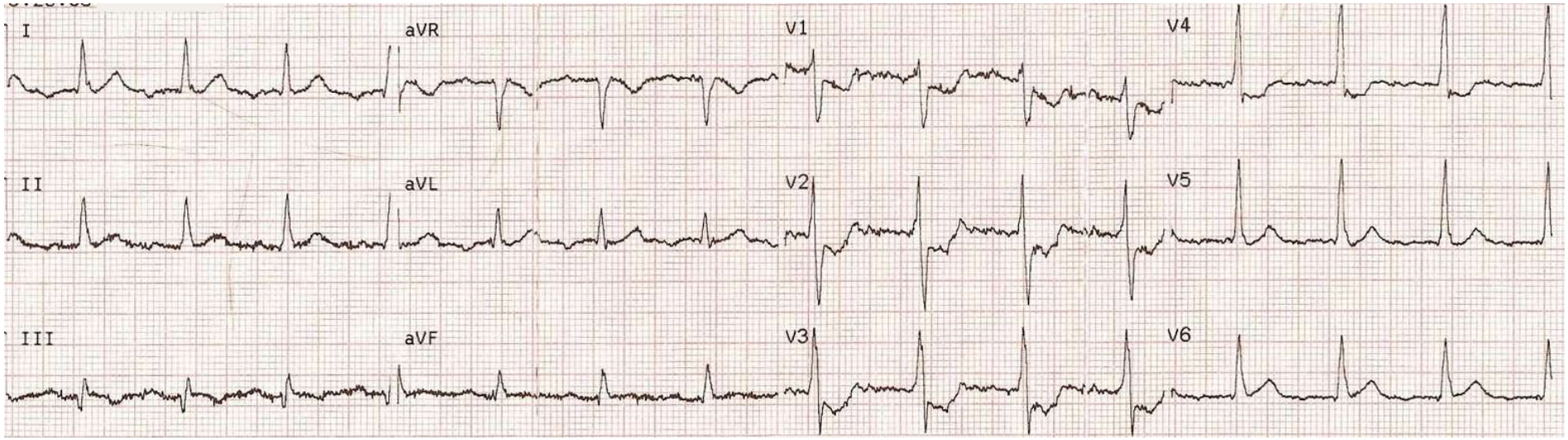

Acute posterior STEMI

- Dominant R wave (R/S amplitude > 1; initial R wave ≥ 40 msec) *with* significant (usually > 2 mm) ST segment depression in at least 2 consecutive leads from V1–V3 *in the absence of* conduction defect or RVH
- Upright T waves are usually evident in the same leads as the dominant R wave

The posterior wall of the left ventricle differs from the anterior, inferior, and lateral walls by not having ECG leads directly overlying it. Instead of Q waves and ST elevation, acute posterior MI presents with mirror-image changes in the anterior precordial leads (V1–V3), including dominant R waves (the upside-down, mirror-image of abnormal Q waves) and horizontal ST segment depression (the upside-down, mirror-image of ST segment elevation).

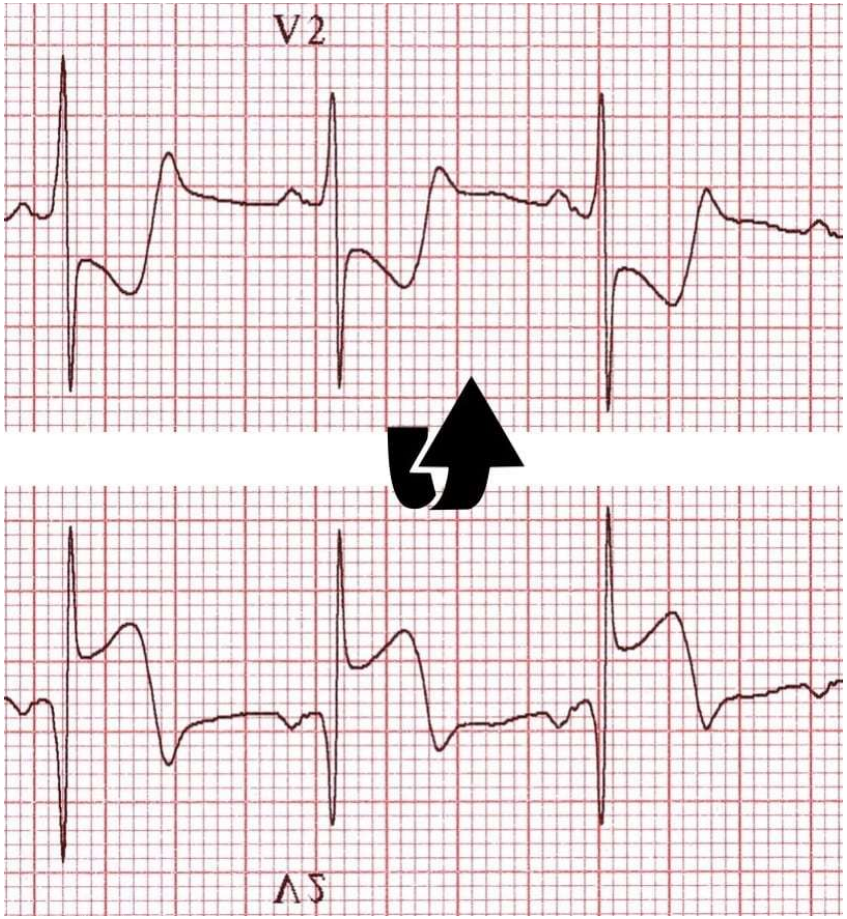

If you flip the paper copy of the ECG over and hold it up to a light so you can see the tracing through the paper, a posterior MI will reveal its true STEMI nature.

Acute posterior infarction is often associated with ECG changes of acute inferior or inferolateral MI, but may occur in isolation.

Posterior chest leads V7–V9 (electrodes placed in the 5th intercostal space at the posterior axillary line, mid-scapular line, and just left of the spine, respectively) demonstrating significant ST segment elevation confirm the presence of acute posterior MI.

RVH, WPW, and RBBB may interfere with the ECG diagnosis of posterior MI since these diagnoses may alter normal QRS activation in leads V1–V3.

In clinical practice, the diagnosis of acute MI is often made without the presence of abnormal Q waves, as many MIs never develop Q waves or develop them hours-to-days after MI has been diagnosed by serum cardiac biomarkers. Recently, the American Board of Internal Medicine (ABIM) Cardiovascular Disease Board Examination eliminated the need for the presence of abnormal Q waves in 2 or more contiguous leads for the diagnosis of MI. However, the diagnosis of old or age indeterminate MI still requires the presence of abnormal Q waves, or in the case of posterior MI, abnormal R waves in V1 to V3.